

SafeBlood Graft™

by SafeBlood® Technologies

1-800-854-4855

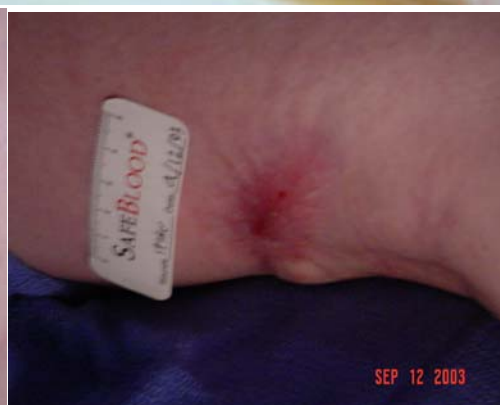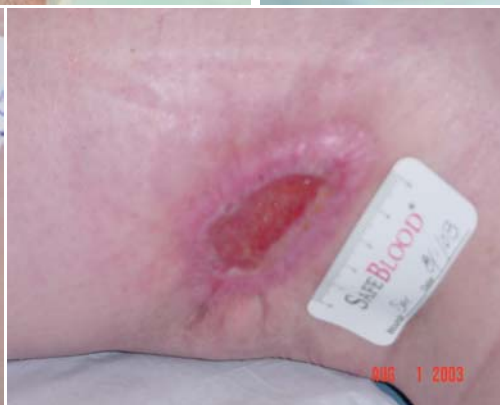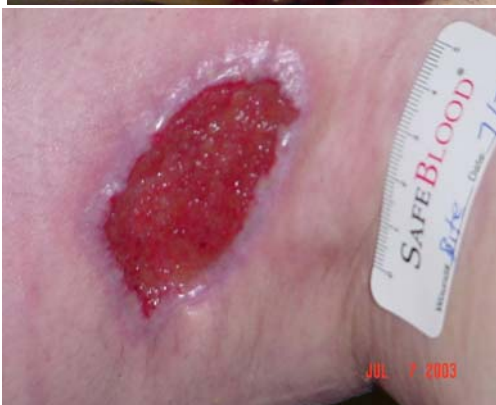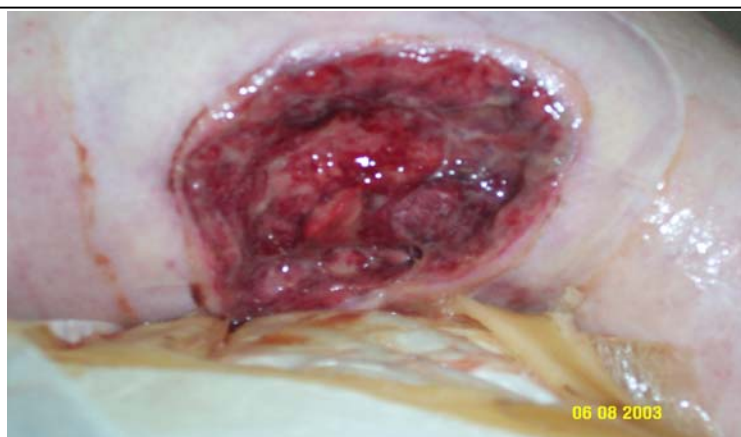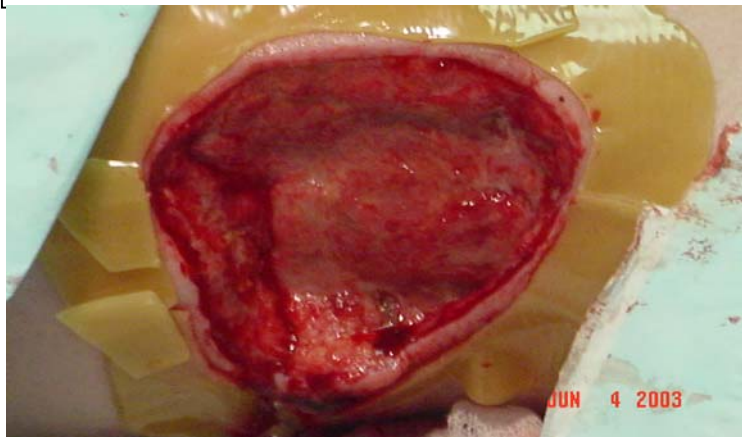
Hx Present Illness/Past Medical Hx/Platelet Graft Therapy:

Wound Etiology: Brown Recluse Spider Bite

Patient presented 4 weeks post-incident

Previous Treatment: Oral and IV antibiotics, Excision of necrotic tissue by plastic surgeon, Given 6 month expectation before any further treatment of flap or skin graft could be effected with expected dimpling with final outcome. Care at time of first treatment involved daily packing with gauze, saline, and covered with gauze wrap.

SafeBlood Graft™: 6-04-03 Eperbole surrounding wound was sharply excised and interior tissues were sharply excised into viable tissue. Approx 50cc of SafeBlood Graft™ was implanted into wound bed and occlusive dressing was applied.



Wound Measurement Table

Volume (cm ³)	396	113.4	17.08	5.148	0	0
Volume Reduction (%)	0%	71%	96%	99%	99%	100%
Length (cm)	11	9	6.1	5.2	4	0
Width (cm)	9	7	3.5	3.3	2	0
Depth (cm)	4	1.8	0.8	0.3	0	0
Date	6/4/03	6/8/03	6/30/03	7/7/03	8/1/03	9/12/03
Week #	1		4	6	8	14
Tissue graft performed?	*					

