

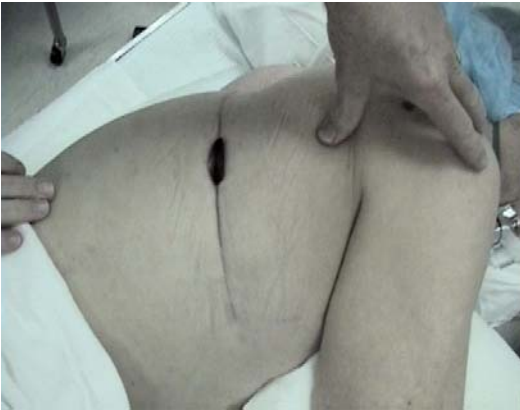SafeBlood Graft Procedure™

using SafeBlood® Technologies

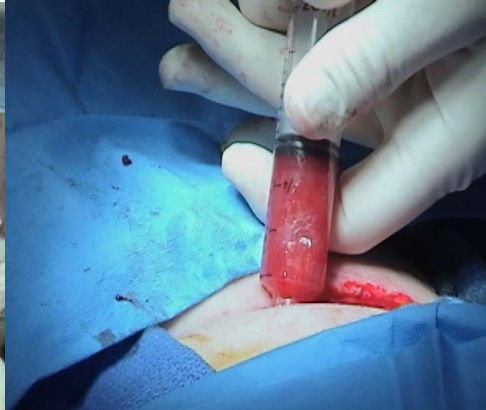
1-800-854-4855

Hx Present Illness/Past Medical Hx/Platelet Graft Therapy:

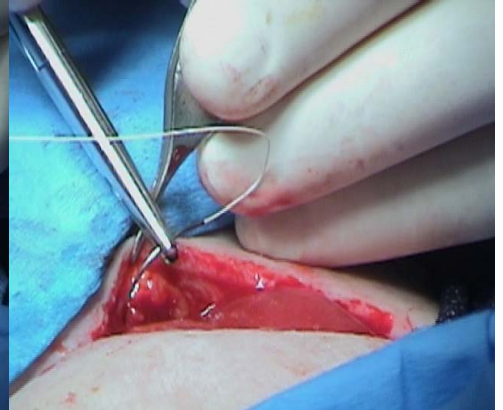
77 y.o. male who developed a surgical dehiscence post partial surgical resection of cancerous lung tissue. The incision was closed primarily except the area noted in first photograph. This persisted for a number of weeks without signs of healing. The wound was sharply debrided and prepared for platelet graft treatment. Approximately 70cc of platelet graft was used to fill the cavity in layers as the wound was sutured from deep to superficial. The wound was dressed with a Tegaderm™ and left undisturbed for 5 days. On day 5, wound was reviewed and the dressing changed. Excellent color and condition. Wound was left until review on day 12, wound was clean, sutures were removed and patient released from care. There have been no signs of infection, abscess, or other complication.



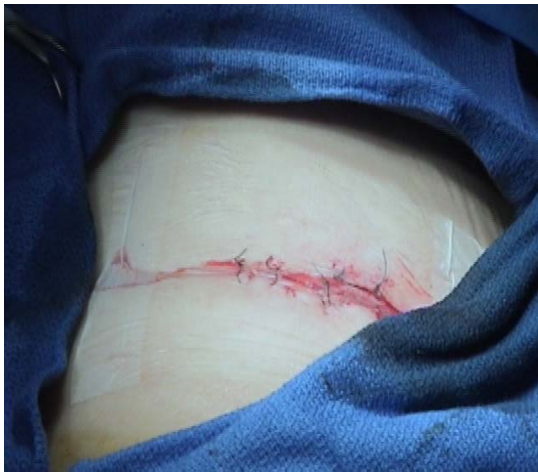5/25/2001



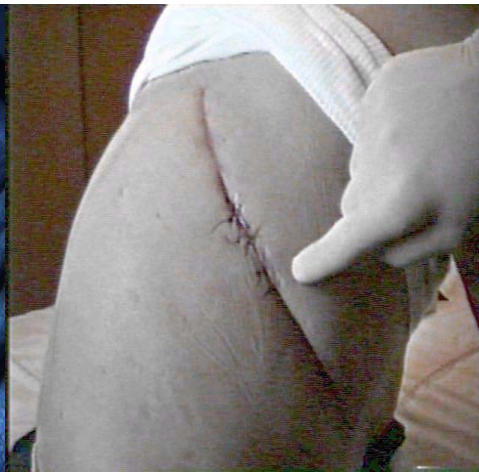5/25/2001



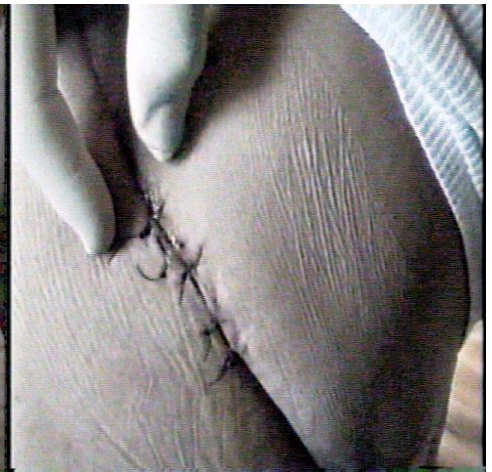
5/25/2001



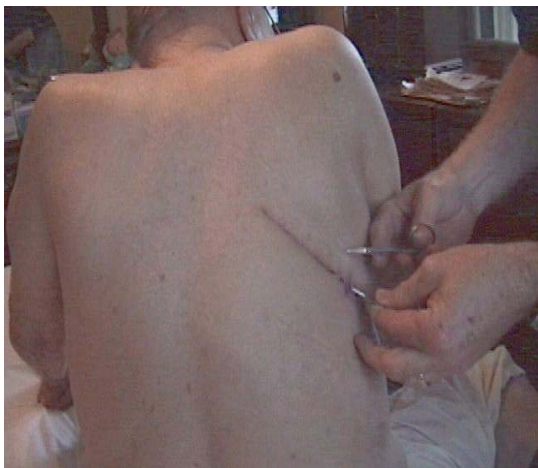5/25/2001



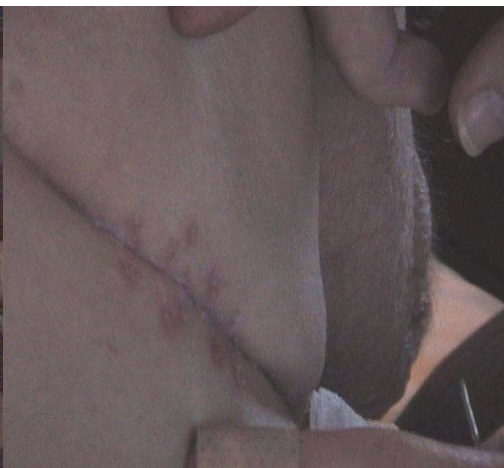5/30/2001



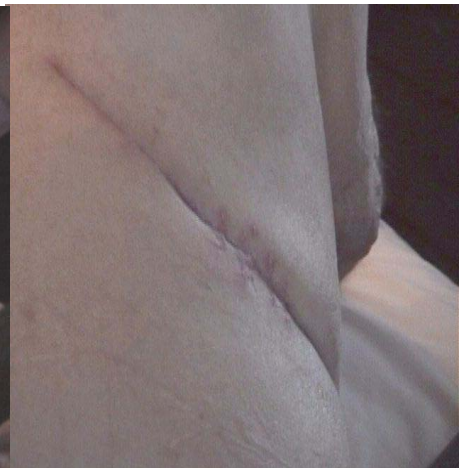5/30/2001



6/6/2001



6/6/2001



6/6/2001